

Bone resorption after alloplastic augmentation of the mandible

H.A. SALEH,* P.J.F.M. LOHUIS* & H.D. VUYK†

*The European Academy of Facial Plastic and Reconstructive Surgery, †Department of Otolaryngology, Facial Plastic and Reconstructive Surgery, Gooi Noord Hospital, Rijksweg, 11261 AN Blaricum, The Netherlands

Accepted for publication 7 January 2002

SALEH H.A., LOHUIS P.J.F.M. & VUYK H.D.
(2002) *Clin. Otolaryngol.* 27, 129–132

Bone resorption after alloplastic augmentation of the mandible

Augmentation mentoplasty is a commonly performed operation especially in conjunction with rhinoplasty. While various materials have previously been used for this procedure, silastic has been the implant of choice for the last three decades. Concerns have been raised due to the occurrence of bone resorption beneath these implants. Controversy prevails as to the cause and the long-term effects of the resorption. It has been suggested by some that the resorption is self-limiting although this has not been confirmed in clinical studies. In total, 40 patients with silastic implants, who had a mean follow-up of 20 months (8–60 months), were studied radiologically. In 21 of them (52%), a degree of resorption from 0.5 to 2 mm was observed. Spearman's rank correlation showed a statistically significant relationship between the degree of resorption and the time lapse since surgery ($P = 0.048$).

Keywords *augmentation mentoplasty silastic bone resorption*

Retrusion of the chin is a deformity that is commonly encountered in patients seeking rhinoplasty.¹ These patients often undergo augmentation mentoplasty to achieve a more aesthetic facial profile, which sometimes reduces the need for excessive reduction rhinoplasty.² Many materials have been tried for augmenting the chin in the past, but solid silastic has gained wide popularity in the last three decades and is, at the present time, the commonest implant in use.³ Some authors have raised concerns about bone resorption beneath these implants, and an ongoing debate regarding the exact causation of resorption and their long-term effects is yet to be settled. We present our experience with 40 patients who underwent lateral mandibular radiographs up to 5 years after the insertion of silastic implants to look specifically for bone resorption.

Materials and methods

Augmentation mentoplasty was performed using two types of silastic prostheses as previously described by the senior author.² The solid type was used for small-to-moderate augmentation, and the extended type for larger augmentation or when it was necessary to blend the lateral mandibular region

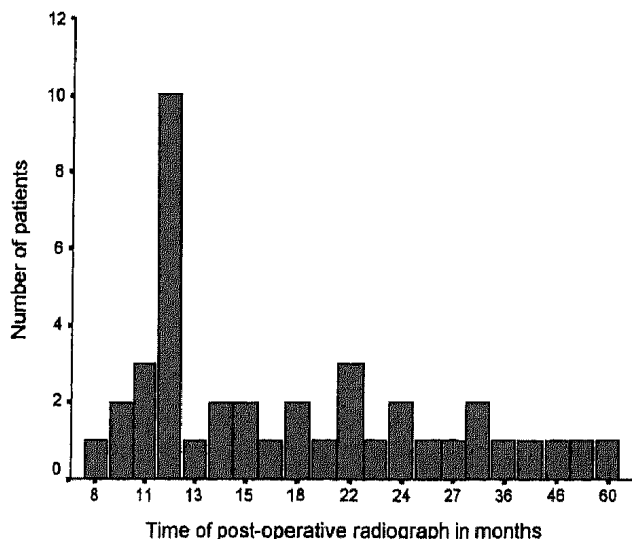
into the cheek. Various implant sizes were used and, when needed, they were carved or their height modified with Gore-tex[®] wafers positioned deep to the implant. The surgery was performed under general anaesthesia except when mentoplasty was carried out without rhinoplasty, in which cases local anaesthesia combined with intravenous analgesia and sedation was sufficient. All implants were inserted through an external skin incision just posterior to the mandibular crease into a subperiosteal pocket. Care was taken to position the implant on the dense bone of the pogonion.²

Between 1990 and 2001, 80 patients underwent the operation. Out of the 80 patients, 5 were lost to follow-up. All efforts were made to arrange lateral mandibular radiographs for as many patients as permitted, and it was possible to obtain these from 40 of them. The latter group will be the centre for further discussions in this article. They were 30 women and 10 men with an age range of 16–50 years (mean = 29.1 years; SD = 8.5 years) (Table 1). All 40 patients were available for follow-up, which ranged from 9 to 60 months (mean = 23 months). Lateral mandibular radiographs were taken in their follow-up visits in a range of 8–60 months postoperatively, with a mean of 20 months (Fig. 1). Rhinoplasty was performed in conjunction with the mentoplasty in 38 patients. One of these had submental liposuction in addition. Two patients did not have rhinoplasty, one had her implant, which was performed elsewhere, exchanged, and the other had

Correspondence: H.A. Saleh, Consultant Otorhinolaryngologist, ENT Department, Charing Cross Hospital, Fulham Palace Road, London W6 8RF, UK (e-mail: hsaleh@hhnt.org).

Table 1. A table showing the age range of the 40 patients who had mentoplasty and postoperative radiology

Age range (years)	Number of patients	Percentage
15–25	16	40%
25–40	21	52.5%
>40	3	7.5%

**Figure 1.** A graph depicting the timing pattern of the postoperative mandibular radiographs.

liposuction. Carving of the prosthesis was needed in five patients, when either anterior or vertical shaves were performed. In addition, Gore-tex[®] wafers were used in 10 patients. All data were collected retrospectively from the medical records, and radiographs were analysed for evidence and degree of mandibular bone resorption.

SPSS version 9 for Windows software was used for the statistical analysis. Spearman's rank correlation was obtained for the relationships between mandibular bony resorption and type/size of the implant, presence or absence of wafers and time the radiograph was taken, in addition to the age and sex of the patients.

Results

All 40 patients were available for follow-up, which ranged from 9 to 60 months (mean = 23 months). They were all happy with the cosmetic results and no complications occurred. A total of 21 patients had some evidence of bone resorption on their lateral mandibular radiograph. The resorption was minimal (less than 0.5 mm) in 14 patients, whereas three patients had 1-mm resorption and four patients had 2-mm resorption (Table 2). Inspecting the level of the bony resorption showed that 12 patients had cephalic resorption at the region of the suprapogonion, at which the bone is less dense. In one patient, whose implant was positioned on the inferior aspect of the

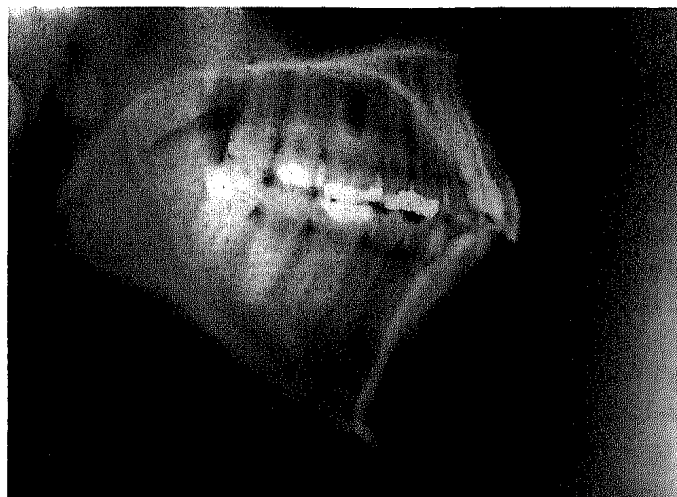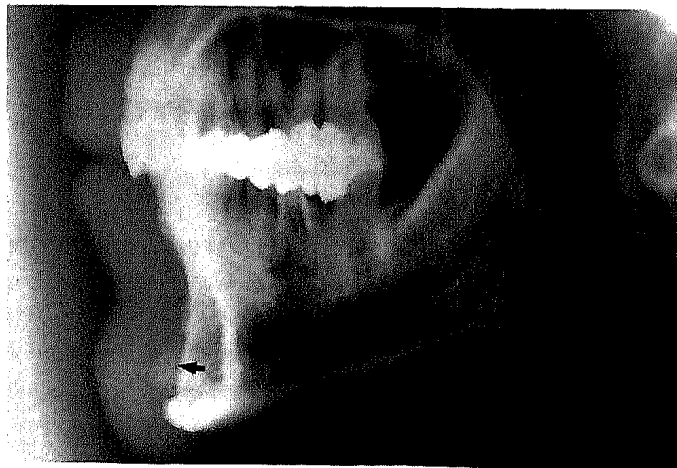
mentum, the resorption was caudal. The rest of the patients had symmetrical resorption under the body of the implant (Table 3, Figs 2 and 3). None of these patients had a noticeable cosmetic change.

Table 2. A table showing the degree of mandibular bony resorption with the corresponding number of patients

Resorption (mm)	Number of patients	Percentage
0.5	14	67%
1	3	14%
2	4	19%

Table 3. A table showing the level of bony resorption with the corresponding number of patients

Level of resorption	Number of patients	Percentage
Symmetric	8	38%
Cephalic	12	57%
Caudal	1	5%

**Figure 2.** A lateral mandibular radiograph showing an area of 0.5 mm of cephalic resorption at the suprapogonion (arrow) 12 months after surgery.**Figure 3.** A lateral mandibular radiograph showing an area of 2-mm symmetrical resorption (arrow) 60 months after surgery.

Using Spearman's rank correlation no statistically significant correlation was found between the bony resorption and type/size of the implant or age and sex of the patients. However, a positive correlation ($r=0.315$ and $P=0.048$) was found between resorption and time lapse of the radiograph, and a negative correlation between resorption and the presence of a wafer ($r=-0.326$ and $P=0.04$).

Discussion

Robinson and Shuken, in 1969, first reported bone resorption beneath mandibular implants.⁴ The incidental discovery of resorption in a patient having a second larger implant prompted them to recall all their patients for radiography. Areas of bone resorption of up to 5 mm in depth were found in 10 out of 14 patients who had subperiosteal silastic or acrylic implants 2–6 years previously. Three years later, Robinson published a second article in which he reported similar resorption in 11 out of 25 patients.⁵ In his opinion, pressure by the implant was the reason for bone resorption. Robinson's articles stimulated other workers to design animal studies looking for various factors leading to bony resorption beneath the implants.^{6,7} Different aetiological factors including pressure, the type of material, the mobility of the implant, the duration of implantation and whether the implant was superficial or deep to the periosteum were suggested. In a study on rabbits' skulls, Jobe *et al.* showed more resorption at 18 months than at 4 months.⁶ They also felt that there was more resorption with subperiosteal implants. In another study, Lilla *et al.* attempted to negate the effect of pressure by using 1-mm-thin implants.⁷ Interestingly, there was no relation of either the duration or the position of implantation in relation to the periosteum to the bony changes. They showed that plain silicone and stainless steel evoked the least reaction on the outer table of the skull. Most erosive to the outer table were the polyurethane foam-backed and the Dacron mesh-backed implants. These views were agreed upon by others who, in addition, suggested that the posterior drift of the implants occurs within 6–12 months after the implantation and stabilizes within 2 years.^{8–10} However, the effect of position of the implant in relation to the periosteum remained controversial.^{7,11} Some authors, who presented their experience with series of mentoplasty patients, noticed that most resorption occurs at the suprapogonion in which the alveolar bone is more vulnerable to pressure and resorption.^{12–14} The areas of resorption were in the region of 0.5–2 mm with follow-up periods of 1–5 years. Furthermore, other surgeons felt that oversized implants were subjected to more mentalis stress leading to higher rates of resorption.^{3,15}

Scaccia *et al.* conducted a survey that covered 11 095 operations performed by 92 surgeons and showed that silicone rubber, which was the commonest material used, had the least complications when compared with acrylic and Proplast.³ They quoted very low incidences of bone resorption although

stating that most respondents admitted to rarely checking postoperatively for radiographic changes. Their survey, therefore, did not show a clear difference between sub- and suprapariosteal insertion, and did not indicate the long-term effects of the implants. There was, however, one case of possible periodontal destruction with the loss of a tooth.

The controversy has been recently revived by Pearson and Sherris who used silastic implants in a randomized, controlled animal trial.¹⁶ They varied the pressure on the implants from minimum to moderate to maximum by compressing them with titanium miniplates. They stated that there was a trend for high-pressure implants to cause less resorption as shown on univariate analysis. They attributed that to the fact that living bone reacts to mechanical stress by depositing actively mineralizing bone at the sites of compression, and actively resorbing bone at the sites of distraction or lack of stress. However, their views may not be fully supported by others owing to the small number of the experiments, and the fact that their conclusions were based on non-statistically significant analysis ($P=0.09$).¹⁷ Another point of interest from their study was the lack of significant difference in resorption between the supra- and subperiosteal implants.

Our institution previously reported bone resorption in the mandibles of 8 out of 13 patients who were studied radiologically.² Most resorption occurred at the region of the suprapogonion and the maximum amount was 1 mm in one patient. These patients are included in the present study in addition to others with longer follow-up. In total, 12 out of 21 patients in this study do have resorption at the suprapogonion. This finding is in agreement with the studies by Friedland *et al.* and Guyuron & Raszewski.^{12,13} Four of our patients had resorption in the region of 2 mm, which is also similar to other reports except for Robinson's, which reported resorption of up to 5 mm.^{4,5} More importantly, our finding of a statistically significant relationship between the degree of resorption and time of postoperative radiography raises concern about the long-term effects of the implants. This is particularly relevant to young patients seeking mentoplasty. We therefore intend to follow this group of patients for a longer period and, if resorption increases significantly, an alternative procedure, such as sliding genioplasty, may have to be considered. The latter procedure, however, takes longer surgical time, causes increased morbidity³ and is associated with a higher risk of mental nerve and tooth injury.¹⁸ There is also a possibility of significant notching of the mandibular ramus in which the horizontal segments are advanced.¹⁸

We did not show a significant relationship between the size of the implant and resorption. This is not in total disagreement with the view that oversized implants cause more resorption, as it could simply indicate that larger implants were suitably used in larger patients. The unexpected suggestion from our data that the presence of Gore-tex[®] wafers is associated with less resorption may be due to the fact that we started using

these more recently, hence the patients with wafers had shorter follow-up periods.

It is interesting that none of the patients with resorption had noticed any cosmetic change. This is probably due to the fact that the majority of resorptions are only a few millimetres in depth and that they occurred over long periods.⁵ Furthermore, malposition of the implant did not occur. This may be due to a better fit in the subperiosteal pocket that we regularly deploy, although the benefit of subperiosteal pockets has not been either confirmed or refuted in other studies.³

Conclusion

We have shown that bone resorption beneath silastic mandibular implants increases with time. The mean period between surgery and the first follow-up radiograph in our group of patients was 20 months. This being relatively short raises concerns about the long-term effects of these implants on mandibular bone resorption. Longer follow-up studies are therefore warranted, not in the least because patients seeking augmentation mentoplasty are of a relatively young age.

References

- 1 DAVIS P.K. (1983) Chin augmentation with rhinoplasty: a tutorial dissertation. *Br. J. Plast. Surg.* **18**, 107–138
- 2 VUYK H.D. (1996) Augmentation mentoplasty with solid silicone. *Clin. Otolaryngol.* **21**, 106–118
- 3 SCACCIA F.J., ALLPHIN A.L. & STEPNIK D.W. (1993) Complications of augmentation mentoplasty: a review of 11095 cases. *Int. J. Aest. Restorative Surg.* **1**, 3–8
- 4 ROBINSON M. & SHUKEN R. (1969) Bone resorption under plastic chin implants. *J. Oral Surg.* **27**, 116–118
- 5 ROBINSON M. (1972) Bone resorption under plastic chin implants. Follow-up of a preliminary report. *Arch. Otolaryngol.* **95**, 30–32
- 6 JOBE R., IVERSON R. & VISTNES L. (1973) Bone deformation beneath alloplastic implants. *Plast. Reconstruct. Surg.* **51**, 169–175
- 7 LILLA J.A., VISTNES L.M. & JOBE R.P. (1976) The long-term effect of hard alloplastic implants when put on bone. *Plast. Reconstruct. Surg.* **58**, 14–18
- 8 SPIRA M. (1973) Editorial addendum. *Plast. Reconstruct. Surg.* **51**, 174
- 9 REES T.D. (1973) Editorial addendum. *Plast. Reconstruct. Surg.* **51**, 174
- 10 KENT J. (1981) Chin and zygomatico maxillary augmentation with proplast. *J. Oral Surg.* **39**, 912–919
- 11 WEBSTER R.C., WHOTE M.F., SMITH R.C. *et al.* (1977) Chin augmentation: subperiosteal and supraperiosteal implants. *Aesthetic Plast. Surg.* **1**, 149–160
- 12 FRIEDLAND J.A., COCCARO P.J. & CONVERSE J.M. (1976) Retrospective cephalometric analysis of mandibular bone absorption under silicone rubber chin implants. *Plast. Reconstruct. Surg.* **57**, 144–151
- 13 GUYURON B. & RASZEWSKI R.L. (1990) A critical comparison of osteoplastic and alloplastic augmentation genioplasty. *Aesth. Plast. Surg.* **14**, 199–206
- 14 SPEAR S.L. & KASSAN M. (1989) Genioplasty. *Clin. Plast. Surg.* **16**, 695–706
- 15 ADAMS J.S. (1987) Grafts and implants in nasal and chin augmentation. *Otolaryngol. Clin. North Am.* **20**, 913–930
- 16 PEARSON D.C. & SHERRIS D.A. (1999) Resorption beneath silastic mandibular implants. Effects of placement and pressure. *Arch. Facial Plast. Surg.* **1**, 261–264
- 17 BLOOMQUIST D.S. (1999) Editorial addendum. *Arch. Facial Plast. Surg.* **1**, 265
- 18 FLOWERS R.S. (1991) Alloplastic augmentation of the anterior mandible. *Clin. Plast. Surg.* **18**, 107–138