

Objective Computerized Determination of the Minimum Cross-Sectional Area of the Nasal Passage on Computed Tomography

Niels H. Bakker, PhD; Peter J. F. M. Lohuis, MD, PhD; Dirk J. Menger, MD;
Gilbert J. Nolst Trenité, MD, PhD; Wytske J. Fokkens, MD, PhD; Cornelis A. Grimbergen, PhD

Objectives/Hypothesis: Current methods that measure cross-sectional areas of the nasal passage on computed tomography (CT) do not determine the minimum cross-sectional area that may be an important factor in nasal airway resistance. Objective measurement of the dimensions of the nasal passage may help in the diagnosis, as well as the choice and evaluation of surgical treatment for upper airway insufficiencies. **Study Design:** Retrospective and clinical study. **Methods:** Software was developed that automatically calculates the minimum cross-sectional area of the nasal passage on CT. **Results:** Evaluation shows that the minimization algorithm in the software reliably calculates the position and orientation of the oblique plane on which the minimum cross-section lies. **Conclusion:** The developed method may be used for objective and observer-independent evaluation of surgical treatment options. **Key Words:** Nasal valve, cross-sectional area, computed tomography, rhinomanometry, resistance.

Laryngoscope, 115:1809-1812, 2005

INTRODUCTION

Measurement of the cross-sectional area of the nasal passage on computed tomography (CT) may be valuable for assessing the effect of different treatment options in nasal valve surgery and for validating other nasal valve measurement methods such as acoustic rhinometry.

Current methods to determine the cross-sectional area of the nasal passage on CT do not determine the section with the minimum area.¹⁻⁷ In many cases, mea-

surements are made on coronal slices,^{1,2,4} resulting in cross-sectional areas that may be up to 50% higher than areas determined on a tilted plane.⁵ Considerable improvement can be obtained when a center line of the nasal passage is either drawn or calculated and areas are determined in planes perpendicular to this line.⁶⁻⁸ However, these methods still do not determine the location and orientation where the minimum cross-sectional area in the passage occurs; furthermore, the presented methods involve steps that require laborious manual input.

Software was developed that allows determination of the cross-sectional area on any oblique plane intersecting with the nasal passage on CT. Furthermore, a minimization procedure was developed that automatically determines the location of the minimum cross-sectional area of the nasal passage. The method was evaluated retrospectively using CT scans from patients undergoing sinus surgery.

MATERIALS AND METHODS

Minimization of Cross-Sectional Area

The minimum cross-sectional area of the nasal passage on CT lies on some oblique plane that slices through the recorded dataset. The position of the "reslice-plane" can be parameterized by a depth coordinate, y , running from anterior to posterior through the nasal passage, and the orientation of the plane can be defined by two angles, Alpha and Beta, the rotation of the plane around the vertical axis and around a horizontal axis, respectively. If Alpha and Beta are 0°, the plane corresponds to the coronal plane; if Alpha is 90° and Beta 0°, the plane corresponds to the sagittal plane; and if Alpha is 0° and Beta is 90°, the plane corresponds to the axial plane.

A software program has been made showing four separate views on the CT data, namely, three orthogonal views (coronal, sagittal, and axial), and the oblique reslice-plane itself (Fig. 1). Furthermore, for evaluation of the results, a fifth view is presented that shows a three-dimensional virtual endoscopic rendering of the CT data (Fig. 2). The three orthogonal views are interlinked so that selecting a point in one view automatically makes the other two orthogonal views run through the same selected point. A green line indicates the intersection line between the reslice-plane and the view.

From the Department of Man-Machine Systems (N.H.B.), Delft University of Technology, Delft, The Netherlands; and the Departments of Otorhinolaryngology—Head and Neck Surgery (P.J.F.M.L., D.J.M., J.N.T., W.J.F.), Center for Facial Plastic and Reconstructive Surgery, and Medical Physics (N.H.B., C.A.G.), Academic Medical Center, Amsterdam, The Netherlands.

Editor's Note: This Manuscript was accepted for publication June 8, 2005.

Send Correspondence to Peter J. F. M. Lohuis, MD, PhD, Department of Otolaryngology—Head and Neck Surgery, Academic Medical Center, Meibergdreef 9 1105 AZ Amsterdam, The Netherlands. E-mail: p.lohuis@nki.nl

DOI: 10.1097/01.mlg.0000174953.66679.a2

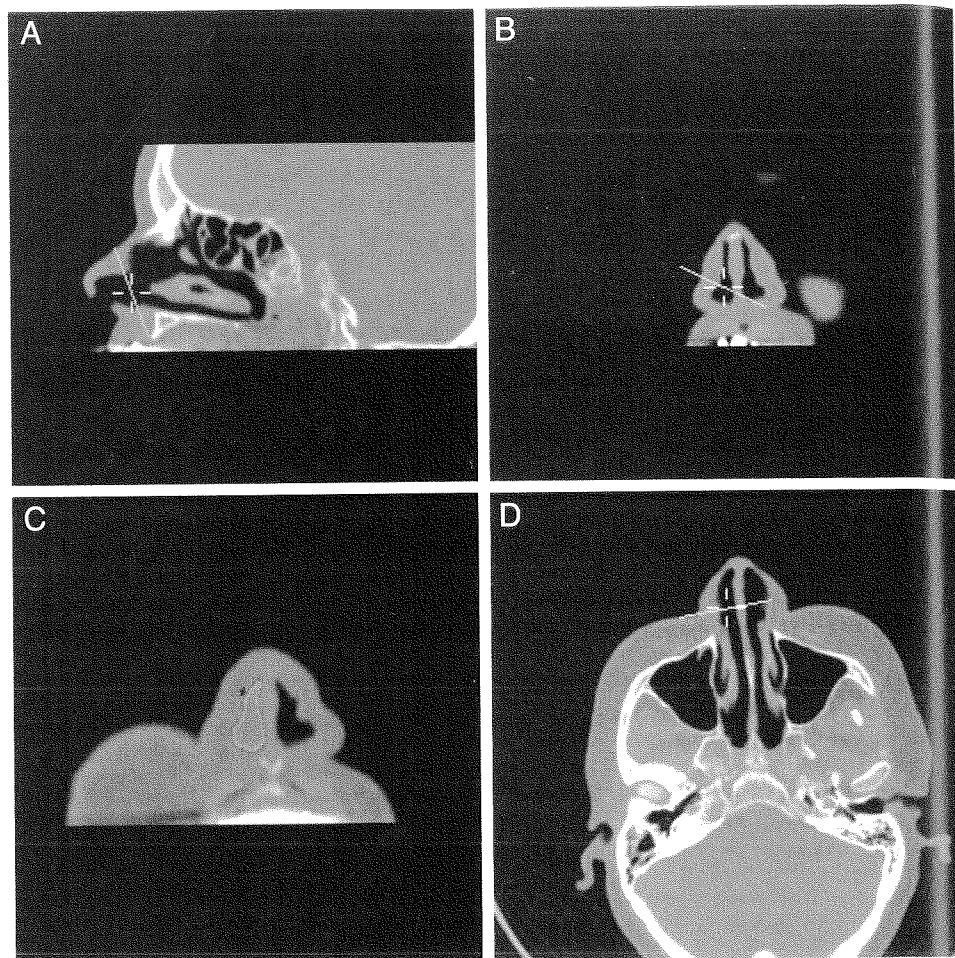


Fig. 1. Views of the computed tomography scan presented by the software. The yellow cross-hair indicates the selected location corresponding in all three views. The green line indicates the intersection of the oblique slice plane with the orthogonal views. (A) The sagittal slice plane. (B) The coronal plane. (D) The axial plane. (C) The oblique slice plane with the determined area of the nasal passage in white.

The cross-sectional area of the nasal passage in a given reslice-plane is determined by automatic segmentation with a fixed threshold. To determine the location and orientation of the reslice-plane that results in the minimum cross-sectional area, an iterative minimization algorithm was implemented that uses the downhill simplex method.⁹ However, depending on the initialization values chosen for the plane parameters, the downhill simplex

might converge on a local minimum rather than the global minimum.

To ensure that a global minimum is found, a three-step approach is adopted. In the first step the user provides an initial estimate of the location of the reslice-plane by selecting a location on the three orthogonal views with a few mouse clicks. In the second step, the downhill simplex is executed 36 times at initialization values distributed regularly around the initial estimate. In the third step, the initialization value that resulted in the minimum result in the second step is used to perform a final downhill simplex with a slower but more accurate tolerance setting.

For the initialization values in the second step, nine different values for the depth coordinate are used, which are 2.0 mm apart and ranging in distance from -8.0 to +8.0 mm to the initial user estimate. At each of the nine depths, four different combinations of the two reslice angles are used, each angle either +20° or -20° from the user estimate.

After completion of minimization, the results are saved for further analysis and the user may verify the results by visual inspection of the intersection line of the plane in the views. Furthermore, a three-dimensional virtual endoscopic visualization is presented of the CT scan, which the user may fly through to inspect the plane (Fig. 2).

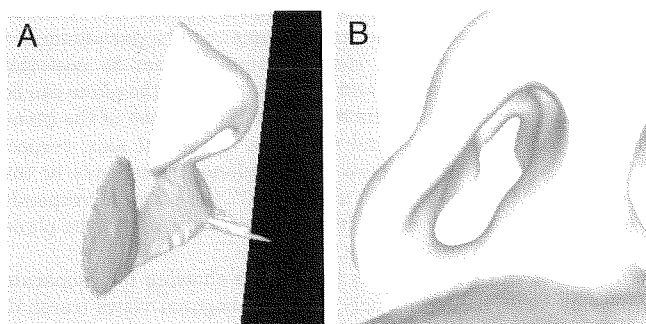


Fig. 2. Two three-dimensional virtual endoscopic views of the computed tomography scan as presented by the software. The green plane is the calculated oblique slice plane containing the minimum cross-sectional area. Users can fly freely through the three-dimensional visualization using their mouse, for instance, to enter the nose to inspect the intersection of the plane with the nasal anatomy to assess whether the minimum cross-section is located at the nasal valve.

Equipment

The CT images for the present evaluation study were acquired with a Philips Mx8000 spiral CT scanner, with the stan-

standard sinus protocol with a pitch of 0.875, at 120 kV and 50 mA. Reconstructions were made with voxels of $0.7 \times 0.324 \times 0.324$ mm. Computed tomography data were Gaussian filtered with SD of 1.0 mm.

The pixel values for a tilted reslice-plane are determined from the neighboring CT voxel values using trilinear interpolation, with a pixel size of the reslice-plane of 0.25×0.25 mm. The algorithms and interfaces are programmed in MS Visual C++ using the VTK and QT toolboxes, and the C++ numerical recipes, and the software runs on a normal PC.

Evaluation

An evaluation of the software and minimization algorithm was performed retrospectively using four randomly selected CT sets from patients undergoing sinus surgery. Decongestion was not applied in these patients before CT scanning. For each CT, the algorithm was tested four times on both nasal passages using random initialization for the location of the reslice-plane, whereas the initialization for the angles was kept at 0° . After the reslice-plane was determined the angles were set to 0° to compute the cross-sectional area on the same location but in the coronal plane. The calculated area and the orientation of the reslice-plane were recorded, as well as the area determined on the orthogonal coronal slice at the same location.

RESULTS

Repeated execution of the algorithm on the same nasal passage with random initializations showed that the algorithm reliably converges on the minimum cross-section with little variation (Table I). In some cases, the orientation of the plane containing the minimum cross-section is far from the orthogonal coronal slice plane (Alpha = 0° , Beta = 0°).

DISCUSSION

The presented method provides an objective and observer-independent measurement of the minimal cross-sectional area of the lumen of the nasal cavity. Results showed that the plane of this minimal cross-sectional area often was tilted with respect to the coronal plane. This finding demonstrates that methods which determine the cross-sectional area only on coronal slices^{1,2,4} are not able to calculate the true minimum cross-sectional area of the nasal cavity.

TABLE I.
Results of the Evaluation of the Algorithm. Values are Means Plus or Minus One Standard Deviation.

CT set	Alpha (degrees)	Beta (degrees)	Minimum Area (cm ²)	% of Coronal area
1 left	24.4 ± 0.5	33.9 ± 1.6	0.56 ± 0.003	56
1 right	-30.8 ± 0.9	41.1 ± 0.6	0.76 ± 0.001	54
2 left	-26.1 ± 0.5	25.6 ± 0.2	0.52 ± 0.002	65
2 right	13.0 ± 0.7	19.0 ± 0.2	0.48 ± 0.001	66
3 left	-18.5 ± 1.2	37.3 ± 0.2	0.55 ± 0.002	*
3 right	-3.8 ± 0.9	-1.3 ± 0.5	0.79 ± 0.004	99
4 left	13.5 ± 0.1	3.3 ± 0.3	0.83 ± 0.002	*
4 right	-8.0 ± 0.4	7.5 ± 0.1	0.80 ± 0.002	*

* The coronal sections runs through the opening in the nostril so that no closed contour in the cross-section was present at the location.

In the present technique, the intersection of the plane of the minimal cross-sectional area is directly shown on orthogonal slices, thereby demonstrating the relation between the anatomy and the narrowest plane of the nasal airway. In general, the narrowest plane of the nasal airway is defined as the internal nasal valve region that by definition includes the caudal end of the upper lateral, the nasal septum, the head of the inferior turbinate, the piriform aperture, and the floor of the nose. Narrowing of parts of this segment can result in impaired nasal breathing. Physical examination of the nose is not always unambiguous in determining the exact anatomical site that causes this functional impairment, making the choice of the surgical procedure (eg, spreader graft or alar batten implantation, inferior turbinoplasty) sometimes troublesome. Our present method to measure cross-sectional area of the nasal passage on CT can objectively assess and visualize in three-dimensions which anatomical structures are involved in the plane of the minimal cross-sectional area, to determine the most adequate surgical plan to reach maximum functional improvement as well as to validate it in the postoperative situation. In the present study, we determined the minimum cross-sectional area in a metrical sense where the highest airflow velocities can be expected. In future studies, we would like to examine flow patterns through this plane to study the question of whether this plane is also the narrowest plane in a physiological sense.

In the presented retrospective evaluation of the algorithm, no decongestion with xylometazoline was applied before CT scanning. In principle, decongestion only reduces the thickness of the mucosa and does not alter the anatomy of the internal nasal valve. However, decongestion before CT scanning in the assessment of a patient with impaired nasal breathing due to inferior turbinate hypertrophy could result in a false minimal cross-sectional area, possibly leading to improper diagnosis and treatment regime. On the other hand, when no decongestion is applied before CT scanning, biases could occur as a result of temporary factors that influence the thickness of the mucosal lining, such as the nasal cycle, allergy, inhalation of dust and smoke, alcohol, or a decrease of nasal resistance attributable to exercise. Nevertheless, decongestion with xylometazoline is more powerful than other factors influencing mucosal thickness and therefore the evaluation of the minimum cross-sectional area to be performed in the most physiological condition. However, it will be interesting to evaluate the effects of topical decongestion on the minimum cross-sectional area on CT and compare this with subjective symptoms of the patients and other tools such as rhinomanometry.

CONCLUSION

Software was developed that automatically calculates the minimum cross-sectional area of the nasal passage on CT, which may be an important factor in nasal airway resistance. Objective and observer-independent measurement of the dimensions of the nasal passage may help in the diagnosis, as well as in the choice and evaluation of surgical treatment for upper airway insufficiencies. Research will be continued, and the method will be

validated against other diagnostic tools such as acoustic rhinometry, rhinomanometry, and nasal peak flow. Moreover, the method will be used to compare cross-sectional areas at the internal nasal valve level before and after surgical procedures such as spreader graft and alar batten implantations.

BIBLIOGRAPHY

1. Min Y-G, Jang YJ. Measurements of cross-sectional area of the nasal cavity by acoustic rhinometry and CT scanning. *Laryngoscope* 1995;105:757-759.
2. Montgomery WM, Vig PS, Staab EV, Matteson SR. Computed tomography: a three-dimensional study of the nasal airway. *Am J Orthod* 1979;76:363-375.
3. D'Urzo, AD, Lawson VG, Vassal KP, Rebuçk AS, Slutsky AS, Hoffstein V. Airway area by acoustic response measurements and computerized tomography. *Am Rev Respir Dis* 1987;135:392-395.
4. Gilain L, Coste A, Ricolfi F, et al. Nasal cavity geometry measured by acoustic rhinometry and computed tomography. *Arch Otolaryngol Head Neck Surg* 1997;123:401-405.
5. Djupesland PG, Rotnes JS. Accuracy of acoustic rhinometry. *Rhinology* 2001;39:23-27.
6. Cakmak O, Coskun M, Celik H, Buyuklu F, Ozluoglu LN. Value of acoustic rhinometry for measuring nasal valve area. *Laryngoscope* 2003;113:295-302.
7. Terheyden H, Maune S, Mertens J, Hilberg O. Acoustic rhinometry: validation by three-dimensionally reconstructed computer tomographic scans. *J Appl Physiol* 2000;89:1013-1021.
8. Poetker DM, Rhee JS, Mocan BO, Michel MA. Computed tomography technique for evaluation of the nasal valve. *Arch Facial Plast Surg* 2004;6:240-243.
9. Press WH, Teukolsky SA, Vetterling WT, Flannery BP. *Numerical Recipes in C++*. Cambridge, UK: Cambridge University Press, 2002.